

Electric stimulation in the treatment of chronic wounds

Rarely are developments in wound management completely new; more often they revisit a wound-healing therapy that has not been fully explored. One such concept is that of electric stimulation or 'E-stim'. The development of E-stim as a therapy is more commonly thought of in relation to relief of pain, i.e. transcutaneous electrical nerve stimulation (TENS) and the rehabilitation of patients with spinal cord injury. However, the potential benefits of E-stim on the healing of chronic wounds need to be further explored. This article will review the use of E-stim in chronic wound management.

Keith F Cutting

KEY WORDS

Leg ulcers

Technology on wound care

Wounds

Electric stimulation

Much remains to be discovered about chronic wounds and their associated care. It is only by achieving a greater understanding of the pathophysiology of chronic wounds that we can hope to make advances in wound care. Chronic wounds by definition are long standing and slow to heal, or non-healing lesions, with the most common being ulcers of the lower limb and pressure ulcers.

Electric stimulation (E-stim) has an extensive history, with records of its use existing from the 17th century (Kanof, 1964; Markov, 1995). However, endogenous bioelectric circuits were not demonstrated until 1830 (Matteucci, 1847, cited by Kloth, 2005). E-stim has acquired a substantial body of evidence (experimental research

Keith Cutting is Principal Lecturer, Buckinghamshire Chilterns University College; Clinical Editor, Wounds UK, and International Board Member of The Association for the Advancement of Wound Care (AAWC)

and clinical trials) to support its use in wound management (Kloth, 1995), in particular for the management of stage 3 and 4 pressure ulcers (Kloth and McCulloch, 1996).

The 'current of injury' and moist wound healing (MWH)

Developing an understanding of chronic wound pathophysiology is important if we are to take full advantage of new treatment modalities. This is underpinned by progressive insight into the complexity of the cellular/biochemical interactions involved, which are orchestrated by cytokines, growth factors and chemokines (Moore, 1999). However, the many detailed accounts of wound physiology rarely offer the reader any insight into the phenomenon of the 'current of injury'.

This concept, which was first introduced by Becker in 1961, indicates that tissue healing is governed by an endogenous electrical current. Should the current leak from the skin as a result of loss of integrity (wounding) a short circuit occurs. This concept has been modified to incorporate contemporary thinking, emphasising restoration of this current through exogenous means. The generated 'current of healing' plays an important role in the healing of injured tissues.

Living tissues possess endogenous bioelectric circuits that contribute to

the regulation of healing in both man and animals (Illingsworth and Barker, 1980; Venable, 1989). The intracellular compartment of healthy skin cells is negatively charged, whereas the intercellular spaces are positively charged. This polarity is a consequence of ionic transport both within the cell and to the extracellular space. This results in what may be called a 'skin battery'. The main ions involved are chloride, calcium, potassium and sodium. Sodium ions are transported from within the cell to the cell membrane. An inward movement of potassium and chloride ions counters this outward movement. The net result is an epidermis that is negatively charged in comparison with deeper tissues (Kloth and McCulloch, 1996).

The concept of moist wound healing (MWH), established for over 40 years (Winter, 1962; Hinman and Maibach, 1963), has heavily influenced the development of modern wound dressings. It is well accepted that occlusive dressings help maintain a moist environment. What is not so well known is that these dressings have been shown to assist in sustaining the wound current at a higher potential than wounds that are exposed to the atmosphere (Cheng et al, 1995). Incorporating the current of healing concept into wound physiology may help to explain why MWH is considered the optimal approach to wound management.

Confirmation of such an association between MWH and the current of healing comes from Jaffe and Venable (1984) who observed that the current of healing is 'switched off' if the wound is allowed to become dry. In contrast, there is low resistance to electrical flow in wounds that maintain a moist environment and demonstrate healing. It is also interesting to note that the voltage, measured in millivolts (mV), that leaks from a wound has been shown to decrease to zero as the wound achieves closure (McGinnis and Venable, 1986).

E-stim technology

Essentially, delivery of E-stim to a chronic wound requires a device that can pass an electrical current across the wound bed. This is usually achieved by placing one electrode in contact with the wound bed and another in contact with the periwound skin close to the wound margin. Treatment is then initiated by control circuitry that generates an appropriate current of

healing for delivery to the wound via the wound electrodes. Many different types of device have been used for wound E-stim and Table 1 shows different types of current used.

Another consideration defining the type of E-stim used is the voltage applied. Voltage may be defined as the difference in energy between two points in a circuit. The voltage delivered to the wound is an important treatment factor as medical E-stim devices have been developed of both high or low voltage.

Delivery of E-stim to a chronic wound requires a device that can pass an electrical current across the wound bed. This is usually achieved by placing one electrode in contact with the wound bed and another in contact with the periwound skin close to the wound margin.

Effect of E-stim on cell function

For the healthy individual, the cellular events involved in healing follow an ordered temporal sequence (Cherry et al, 2000) that, in the absence of complicating factors such as infection, should lead to a healed wound. For the purpose of discussion it is convenient to divide healing into the phases of haemostasis, inflammation, granulation tissue formation and re-epithelialisation (Cherry et al, 2000). Although distinct cellular events

occur within each phase there is considerable overlap of each, and cells dominant in one phase may influence events within succeeding phases.

Negative influences from systemic co-morbidities such as peripheral vascular disease or diabetes, and local factors such as bacterial critical colonisation or infection, may induce, delay or halt the healing process, thus forming chronic non-healing wounds. These wounds exhibit many features (Table 2) generated as a consequence of chronic inflammation (Loots et al, 1998) and functionally defective granulation tissue that is not found in a normally healing wound.

Capillaries in defective granulation tissue are tortuous and surrounded by fibrin cuffs (Higley et al, 1995). Fibroblasts have decreased proliferative capacity, possibly as a consequence of an increase in the proportion of senescent (non-dividing) cells (Mendez et al, 1998). High levels of proteases in the chronic wound, derived from inflammatory cells and senescent fibroblasts, result in a degradation of extracellular matrix (ECM) which prevents keratinocyte migration and re-epithelialisation (Herrick et al, 1992).

The overall picture found within chronic wound tissue is not one of decreased cellular activity but rather disorder where unregulated cellular functions, such as protease production, are found. In order for healing to be initiated and then proceed to wound closure, order has to be established.

The changes required are demonstrated at the cellular level. The chronic inflammatory cytokine profile found in the non-healing wound is converted by successful wound management to a profile characteristic of a resolving inflammatory response found in a healing wound (Fivenson et al, 1997).

Initiation of healing for a chronic wound at a cellular level requires that barriers to healing, such as high levels of bacteria in wound tissue or necrotic tissue, are removed (Schultz et al, 2003),

Glossary of terms

Anode: a positively charged electrode

Cathode: a negatively charged electrode

Electrode: a conductor used to make electrical contact within a circuit

Endogenous: originating or produced within an organism

Ion: an atom or group of atoms that has an electrical charge (positive or negative)

Voltage: The difference in energy between two points in a circuit

Table 1

Types of current used for electric stimulation in wounds

Mode	Explanation
Direct current (DC)	Electric current that flows through a conductor in one direction only. Usually of very low intensity and designed to replicate endogenous currents
Alternating current (AC)	Electric current in which the direction of the flow is reversed at frequent intervals. It is important to note that the current is never 'off' between cycles. AC is the standard type of current used in electrical distribution systems with European domestic supply being 50 cycles per second
DC or AC pulsed	The brief pulsed delivery of DC or AC electrical current in microseconds or milliseconds, with each pulse being separated by an 'off' period

followed by wound management with appropriate dressings that maintain an optimal healing environment. Many chronic wounds respond positively to good wound care but this may be slow, with a substantial minority remaining refractory to treatment with adjunctive or alternative therapy required.

Defects within the chronic wound are multifactorial (see *Table 2*) and treatment may require multiple modalities. For example, although modulation of chronic inflammation is required for the initiation of healing, there may be a requirement for its conversion to a resolving acute-type inflammation. This will produce the appropriate growth factors required for re-establishment of normal granulation tissue (Moore, 1999).

In order for healing to proceed, fibroblasts need to migrate from adjacent non-involved dermis along with fresh endothelial cells in order to form functional capillaries. Once a functional extracellular matrix (ECM) has formed, re-epithelialisation may be accelerated if an appropriate stimulus is provided. There is evidence that E-stim

may impact on the healing of chronic wounds at a number of points in the healing process. The following section will consider how E-stim may interact in healing at the cellular level in each of the phases of healing.

Although the mechanism of bacteriostasis induced by therapeutic E-stim has not been fully explained, it is clear that this is not the result of temperature or pH changes at the electrodes.

Antibacterial effects

Bacterial growth in wound tissue is often a significant factor contributing to delayed healing or failure to heal (Bowler et al, 2001). Even in the absence of clinical signs of infection, chronic wounds are frequently colonised (Hansson et al, 1995). Bacteria are a potent source of proinflammatory stimuli over a prolonged period, resulting in chronic inflammation and wound chronicity. For this reason, resolution of any

bacterial imbalance is considered fundamental to the healing of chronic wounds (Schultz et al, 2003).

Low-level E-stim has been shown in vitro to inhibit the growth of three organisms frequently isolated from chronic wounds — *Staphylococcus aureus*, *Escherichia coli* and *Pseudomonas aeruginosa* (Kincaid and Lavoie, 1989). Although the mechanism of bacteriostasis induced by therapeutic E-stim has not been fully explained, it is clear that this is not the result of temperature or pH changes at the electrodes (Szuminsky et al, 1994). Pulsed electrical fields are used to kill bacteria in industrial processes where the antibacterial effect is attributed to membrane pore formation (Pol et al, 2000). However, the voltages used here are in excess of those used for therapeutic purposes.

These findings can be translated into in vivo experiments where E-stim effects have been measured on intact human skin (Bolton et al, 1980). The antibacterial effect was considered to be caused by an electrochemical effect. Similar in vivo antibacterial effects have

Table 2

Reversal of chronic wound defects by electric stimulation

Defects	Electric stimulation bioactivity	Effect
Bacterial bioburden	Antibacterial, especially at cathode	Eliminate chronic inflammatory stimulus
Chronic inflammation: - Macrophages with defective function - Activated neutrophils - Increased proteases	Recruit fresh macrophages (carry negative charge)	Stimulate a resolving inflammation Normalise growth factor/cytokine profile Decrease protease production
Defective ECM	Stimulate protein synthesis Increase oxygen levels	Enhance ECM production Improve collagen organisation
Defective granulation: - Senescent fibroblasts	Stimulate fibroblast proliferation (positively charged and hence attracted to cathode) Stimulate VEGF production	Increase number of non-senescent cells Increase angiogenesis
Defective capillaries		
Defective re-epithelialisation: - Non-migrating keratinocytes	Stimulate keratinocyte migration towards cathode	Stimulate re-epithelialisation

ECM= extracellular matrix; VEGF = vascular endothelial cell growth factor

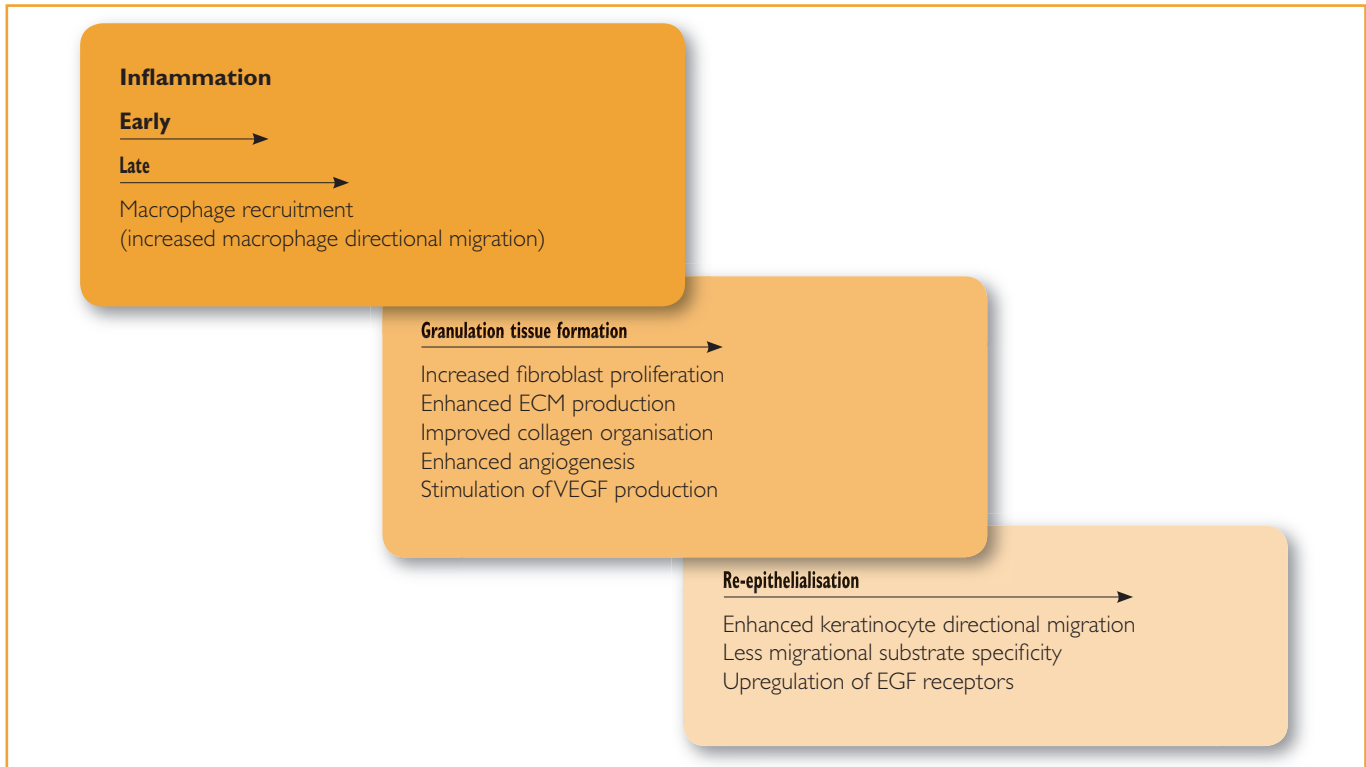


Figure 1. The phases of wound healing: modification of cell function by electrical stimulation. ECM = extracellular matrix; VEGF = vascular endothelial cell growth factor; EGF=Epidermal growth factor.

been demonstrated in the successful treatment of *P. aeruginosa* infections of experimental incisional wounds in rabbits (Rowley et al, 1974). These effects were generated by the use of cathodal direct current (DC) stimulation. Similar treatments applied to infected femurs in rodents were found to exert a bacteriostatic effect (Barranco, 1999).

Wheeler et al (1971) found that bacterial proliferation within human pressure ulcers was inhibited within 3 days of e-stim treatment, and continuing treatment resulted in resolution of infection. While the majority of evidence for a direct E-stim antibacterial effect is based on in vitro and in vivo evidence, there is a body of evidence to suggest that these effects may be exerted in human chronic wound tissue.

Inflammation

E-stim is implicated in the recruitment of neutrophils (Fukushima et al, 1953) and macrophages (Orida and Feldman, 1982) to the wound. Macrophages

There is evidence in experimental wounds that E-stim can bring about wound contraction by exerting a direct effect on fibroblasts in granulation tissue.

and neutrophils are the major cellular components of the inflammatory phase of healing (Loots et al, 1998). While both are important in protecting against infection, the macrophage is thought to play an additional central role in regulating the healing process by producing cytokines and growth factors (Clark, 1996).

The migration rate of macrophages is accelerated in electrical fields in vitro (Cho et al, 2000), with directional migration to the anode being generated by active directional cell movement (Orida and Feldman, 1982). The increased directional migration of macrophages is consistent with an acceleration of the inflammatory phase

found in E-stim-treated rat wounds (Taskan et al, 1997). Interestingly, the rapid resolution of the inflammatory response was followed by early initiation of the proliferative phase of healing and an increase in wound tensile strength compared to sham-treated control wounds. At first consideration this may appear inconsistent with the decreased inflammation found in pressure ulcers treated with E-stim (Cukjati and Savrin, 2004). Chronic inflammation needs to be resolved before functional granulation tissue is produced, and this process would be assisted by E-stim-driven recruitment of a normally functioning population of fresh macrophages (Moore, 1999).

Granulation tissue formation

Formation of normally functioning granulation tissue depends upon the proliferation of fibroblasts and endothelial cells, followed by the production of ECM that allows keratinocyte migration and the production of functioning capillaries.

This supports healing with an adequate supply of nutrients and oxygen.

E-stim enhances proliferation and protein synthesis of cultured human fibroblasts (Bourguignon and Bourguignon, 1987; Goldman and Pollack, 1996) and has been demonstrated to increase collagen deposition in excisional wounds in rabbits (Canseven and Atalay, 1996) and diabetic mice (Thawer and Houghton, 2001). E-stim enhances collagen fibre alignment that is better organized by comparison to (Reger et al, 1999) control wounds (Brown et al, 1989; Cruz et al, 1989), and explains the finding on enhanced tensile strength Taskan et al (1997).

Wound fibroblasts (myofibroblasts) also contribute to closure by drawing the wound margins together (Gabbiani, 2003). There is also evidence in experimental wounds that E-stim can bring about wound contraction by exerting a direct effect on fibroblasts in granulation tissue (Brown and Gogia, 1987).

Angiogenesis, or the formation of new vasculature, requires microvascular cells to migrate, proliferate, elongate and organise to form tubules. Vascular endothelial cell growth factor (VEGF) plays an important role in stimulation of angiogenesis (Nissen et al, 1998). The improved dermal capillary formation seen in human ischaemic wounds following E-stim (Goldman et al, 2004) may be a consequence of VEGF production (Cuevas and Asin-Cardiel, 2000). Production of VEGF is stimulated by electric fields of physiological magnitude interacting directly with receptors on the surface of endothelial cells without the need for involvement of other cell types (Zhao et al, 2004).

Re-epithelialisation

The process of re-epithelialisation requires that keratinocytes from the wound margins migrate in a coordinated fashion across the ECM (which is formed by fibroblasts in granulation tissue) to close the wound effectively. A number of studies have demonstrated keratinocyte migration towards

the cathode of an electrical field (Nishimura et al, 1996; Sheridan et al, 1996; Xhao et al, 1999).

Under normal circumstances, keratinocytes exhibit substrate preference, but this is eliminated with E-stim so that they migrate equally well on matrices composed of types I and IV collagen, fibronectin, laminin, and even tissue culture plastic (Sheridan et al, 1996). This may be of benefit in the chronic wound where the provisional extracellular matrix is likely

One of the most marked cellular effects of E-stim...is the stimulation of directional cellular migration. This has particular therapeutic significance, as cell migration is required during each phase of healing.

to be deficient in some components required to support keratinocyte migration. E-stim may mediate its effect on directional migration by upregulating expression of receptors for epidermal growth factor, making them more responsive to limiting levels of the factor in the chronic wound environment (Zhao et al, 1999).

Potential mode of action of E-stim on chronic wounds

E-stim has been demonstrated to have potentially multiple effects on all phases of healing (*Figure 1*).

One of the most marked cellular effects of E-stim demonstrated in the references cited above is the stimulation of directional cellular migration. This has particular therapeutic significance, as cell migration is required during each phase of healing. Monocytes move (extravasation) from the blood during inflammation and as they mature into functional macrophages they have to migrate into the site of injury and then control healing by the release of growth factors. Fibroblasts and endothelial cells have to migrate into the wound

from the surrounding dermis and proliferate at the wound site forming granulation tissue. Finally, to achieve wound closure, keratinocytes migrate from the wound margin and cover the wound bed (Cherry et al, 2000). E-stim can contribute by directly enhancing the migratory capacity of keratinocytes and indirectly by stimulating production of ECM that allows keratinocyte migration over the wound bed (Canseven and Atalay, 1996). Any stimulation of these migratory processes has potential benefit to the chronic wound (*Table 2*).

Other effects, such as fibroblast stimulation of cell proliferation, may accelerate granulation tissue formation and stimulate healing of chronic wounds by a consequent decrease in the proportion of senescent fibroblasts in granulation tissue (Harding et al, 2005).

In the chronic wound, specific signals provided by growth factors and cytokines are disordered and this is one of the consequences of chronic inflammation. The multi-modal bioactivity of E-stim contributes to the removal of the negative influence of bacterial bioburden. This assists in establishing the regulatory function of macrophages freshly attracted to the wound site. The benefit of E-stim for treating wounds with multifactorial defects is that it can provide stimuli to diverse cells and enhance healing by stimulating cellular processes in each of the healing phases.

E-stim and chronic wounds: the literature

It can be difficult to compare outcomes reported in the literature as there are differences in methodology and therapeutic modality, and the nature of such trials is that the number of participants tends to be small. On the whole they present positive findings. Kloth (1995) presents the hypothesis that a therapy closely mimicking the 'natural' (bioendogenous) low voltage (DC) is of therapeutic value. It is also interesting to note that most wound physiology texts state that cells are attracted to damaged tissue through a process called chemotaxis but little attention is given to the process of 'galvanotaxis'.

Kloth (1995) states that galvanotaxis is the attraction of cells (e.g. neutrophils, macrophages, fibroblasts, etc.) through the bioelectrical system. If this process is inhibited, e.g. by desiccation or by applying non-conductive agents to the wound, this will affect adversely the endogenous bioelectric circuitry. Non-conductive agents include petroleum products and debriding enzymes (Kloth, 1995). Additionally, where factors that have an adverse effect on healing occur, such as infection, galvanotaxis is reversed and neutrophils are then attracted to a negative charge (Kloth, 1995).

Carley and Wainapel (1985) conducted a controlled trial using low-

intensity DC E-stim or standard wet-to-dry dressings/whirlpool therapy on 30 patients with leg or pressure

It would appear that a temporary increase in tissue oxygen level is achieved following E-stim and that this increase in oxygen may bestow a beneficial effect on chronic wound healing.

ulcers. There was up to a 2.5 times faster healing rate in the E-stim group. Additionally, the wounds treated with E-stim required less debridement and

patients reported decreased pain at the wound site. Interestingly, no wound infections occurred in the E-stim group.

Wood et al (1993) used low-intensity DC but this time in a pulsed waveform. This was a double-blind, multicentre study and focused on stage II and III chronic pressure ulcers. In the treatment group of 43 patients, 25 ulcers healed in 8 weeks. In the placebo group, only one ulcer healed and most of the others increased in size. The authors concluded their study by stating that pulsed low intensity DC current is of value in the treatment of stage II and III chronic pressure ulcers.

Kloth and Feedar (1988), in a randomised, blind, crossover study, used a pulsed high voltage (100–175v) current to treat unresponsive pressure ulcers. Sixteen patients were allocated to treatment (n=9) or control groups (n=7) with treatment for 45 minutes daily, five days per week. All of the treatment group ulcers healed (average 7.3 weeks) with a mean healing rate of 44.8% per week. The ulcers in the control group increased in size by a mean of 29%. A sub-group of three patients in the control group were moved to the treatment group and then achieved a healing rate of 38% per week (100% healing in 8.3 weeks mean). It is interesting to note that, despite the positive findings in this paper, Kloth appears to have abandoned the high-voltage approach as he subsequently recommended low-voltage stimulation (Kloth, 1995).

Cells within wound tissue require oxygen for the normal metabolic processes involved in healing. Two studies have investigated the effects of E-stim on tissue oxygenation in patients with diabetes. Dodgen et al (1987) found that patients with diabetes (n=10) showed a significant but delayed increase in transcutaneous partial pressure of oxygen after 30 minutes of E-stim. Peters et al (1998) found that there was a significant increase in partial pressure of oxygen within 5 minutes following E-stim. It would appear that a temporary increase in tissue oxygen levels is achieved following E-stim and that this increase in

Figure 2. A new E-stim dressing technology

The E-stim wound dressing product, POSIFECT™ RD (Biofisica, Hampshire, UK) comprises a disposable, one-time use dressing (see below; The white case = electric modulating assembly; Raised flap showing cathode paddle beneath; The anode ring is embedded in the hydrogel which is on the underside of the dressing). Within its matrix it contains a miniature electrical circuit that creates a constant, low-intensity, DC electrical field, mimicking endogenous bioelectric current. The electrical field is transmitted to the wound bed through the dressing matrix; a conductive, oxygen-permeable hydrogel. The hydrogel maintains moisture within the wound bed in line with current concepts of Moist Wound Healing best practice and can be used under compression according to clinical need.



The design of the circuit builds on the positive E-stim findings described in this article. The cathode is placed in the centre of the wound, building on antibacterial reports associated with cathodal DC (Kloth, 2005). It attracts the positively charged fibroblasts and keratinocytes to the centre of the wound, contributing to competent extracellular matrix formation. At the same time defective macrophages involved in the inflammatory response are attracted to the anode ring at the periphery of the wound. This helps restore the balance found in normally healing wounds.

oxygen may bestow a beneficial effect on chronic wound healing.

Houghton et al (2003) studied the impact of high-voltage pulsed current on 27 subjects with 42 chronic leg ulcers of venous, arterial or diabetic aetiology. The subjects were randomly assigned to the treatment group (n=14) or the placebo group (n=13). In this double-blind, prospective study subjects received E-stim or sham treatment for 45 minutes, three times each week for 4 weeks. The researchers found that E-stim reduced the surface area of the wounds by approximately 50% in the 4-week study period. They conclude by stating that E-stim 'should be used to accelerate wound healing in chronic vascular leg ulcers'.

In a study of 185 pressure ulcers on 80 patients with spinal cord injury, Baker et al (1996) studied the effects of three different waveforms and compared these with placebo controls. The authors state that the good responders (n=104) demonstrated significantly better healing rates when receiving asymmetric biphasic current in comparison with the microcurrent or control groups. A slightly lower (not significant) healing rate was found in those wounds that received symmetric biphasic stimulation. A subset (n=11), where progress in healing was observed during the control phase, demonstrated a significant increase in healing when receiving E-stim. The authors suggest that the addition of E-stim to a 'slow-to-heal' wound should accelerate healing.

Stiller et al (1992) conducted a prospective, randomised, double-blind, placebo-controlled study on recalcitrant venous ulcers. E-stim was applied for three hours each day over 8 weeks adjunctive to wound dressings. The active treatment group (n=31) benefited with a 47.7% decrease in the surface area, whereas the placebo group's (n=31) wounds increased by 42.3% over the 8-week period. Overall, 50% of the experimental group's ulcers healed or showed a marked improvement but the placebo group showed no improvement.

In a meta-analysis of the effect of electrical stimulation on chronic wound healing, Gardner et al (1999) analysed the findings of 15 studies. Her conclusions state that, although further research is required to identify which E-stim devices are most effective, based on the average rates of healing E-stim increases the rate of chronic wound healing by 144%, thus inferring a positive effect on chronic wound healing.

The association between MWH and 'the current of healing' may encourage clinicians to consider E-stim as a therapy, supported by a reputable body of evidence, for wounds that have resisted attempts using conventional approaches.

Recent e-stim findings

In a randomised, double-blind, crossover study, Feldman et al (2005) enrolled 15 patients with stage 3–4 pressure ulcers. Six patients met the identified nutritional requirements of the study and four patients completed the trial, with two receiving active treatment and two sham treatment. Patients received their treatment in blocks of 8 weeks. Those patients that received the sham treatment then received 8 weeks of low-level DC using a new E-stim treatment that has recently been developed — POSiFECT™ RD (Biofisica, Hampshire). All patients were followed for 16 weeks. The researchers found improvements in the healing rate of pressure ulcers in first to third weeks in the E-stim group. As a consequence of this study, the protocol was adjusted to three weeks on, followed by one week off E-stim therapy.

This treatment regime was used in a recently reported case study that recorded a dramatic improvement in a 70-year-old woman with a leg ulcer resulting from elective orthopaedic surgery (Hampton and King, 2005). The ulcer was painful, with copious infected

exudate and measured 30.2cm² in surface area. Conventional therapy failed to make any improvement and that is why E-stim was instigated.

The regime consisted of POSiFECT™ RD bioelectric wound care dressing with three weeks of continuous treatment, including external graduated compression, and then one week's rest on conventional compression therapy and absorbent dressing only. By the fourth week the infection appeared to have resolved (reduced level of exudate and wound bed of clean appearance) and the wound was reducing in size. By week 8 abundant granulation tissue was observed and epithelial islands were apparent. The wound was completely healed in just over 4 months and the patient was able to resume her normal activities.

It should be noted that while case studies do not occupy a high ranking in the hierarchy of evidence, they do provide useful insight of clinical experience as recorded by the clinician. Figure 2 describes the theory behind how the E-stim dressing therapy POSiFECT™ RD may have a positive effect on wound healing.

Conclusion

Faced with a departure from conventional approaches to wound care (dressings/moist wound healing) and the adoption of a physical modality, the clinician may feel that they are taking a step into the unknown. It is important to remember that a similar challenge faced those clinicians in the 1960's following the work of Winter (1962). His questionable approach, at the time, of advocating an environment that promotes moisture at the dressing interface has been supported by the subsequent generation of wound dressings. However, it cannot be ignored that not all wounds heal despite using the MWH approach. The association demonstrated above between MWH and the current of healing may encourage clinicians to consider E-stim as a therapy, supported by a reputable body of evidence, for wounds that have resisted attempts using conventional approaches.

Current of healing is a concept that could unify the MWH and E-stim approaches to wound care and could herald the advent of a new treatment paradigm. The evidence presented in this article suggests that the addition of E-stim has the potential to 'kick start' healing in chronic wounds, when a moist environment alone has failed. **WUK**

References

Baker LL, Rubayi S, Villar F, Demuth SK (1996) Effect of electrical stimulation waveform on healing of ulcers in human beings with spinal cord injury. *Wound Repair Regen* 4: 21–8

Barranco SC (1999) In vitro effect of weak direct current on *Staphylococcus aureus*. *Clin Orthop* 100: 250–7

Key Points

- ▶▶ Tissue healing is modulated by an endogenous electric current and this 'current of healing' plays an important role in the healing of injured tissue.
- ▶▶ Electric stimulation (E-stim) has acquired a body of evidence to support its use in wound management.
- ▶▶ E-stim has been shown to have potentially multiple effects on all phases of wound healing.
- ▶▶ 'Current of healing' is a concept that could unify the Moist Wound Healing and E-stim approaches to wound care, heralding the advent of a new treatment paradigm.
- ▶▶ The evidence presented in this article suggests that the addition of E-stim has the potential to 'kick-start' healing in chronic wounds, when a moist environment alone has failed.

Becker RO (1961) The bioelectric factors in amphibian-limb regeneration. *J Bone Joint Surg Am* 43-A: 643–56

Bolton L, Foleno B, Means B, Petrucelli S (1980) Direct-current bactericidal effect on intact skin. *Antimicrob Agents Chemother* 18(1): 137–41

Bourguignon GJ, Bourguignon LY (1987) Electric stimulation of protein and DNA synthesis in human fibroblasts. *Faseb J* 1(5): 398–402

Bowler PG, Duerden BI, Armstrong DG (2001) Wound microbiology and associated approaches to wound management. *Clin Microbiol Rev* 14(2): 244–69

Brown M, Gogia PP (1987) Effects of high voltage stimulation on cutaneous wound healing in rabbits. *Phys Ther* 67(5): 662–7

Canseven AG, Atalay NS (1996) Is it possible to trigger collagen synthesis by electric current in skin wounds? *Indian J Biochem Biophys* 33(3): 223–7

Carley PJ, Wainapel SF (1985) Electrotherapy for acceleration of wound healing: low intensity direct current. *Arch Phys Med Rehabil* 66(7): 443–6

Cheng K, Tarjan P, Oliveira-Gandia M et al (1995) An occlusive dressing can sustain natural electrical potential of wounds. *J Investigative Dermatol* 104(4): 662–5

Cherry GW, Hughes MW, Ferguson MWJ et al (2000) Wound healing. In: Morris PJ, Wood WC, eds. *Oxford Textbook of Surgery*. 2nd edn. Oxford University Press, Oxford: 131–62

Cho MR, Thatte HS, Lee RC, Golan DE (2000) Integrin-dependent human macrophage migration induced by oscillatory electrical stimulation. *Ann Biomed Eng* 28(3): 234–43

Clark RAF (1996) Wound repair: overview and general considerations. In: Clark RAF, ed. *The Molecular and Cellular Biology of Wound Repair*. 2nd edn. Plenum Press, London: 93–131

Cuevas P, Asin-Cardiel E (2000) Electromagnetic therapeutic angiogenesis: the next step. *Neurol Res* 22(4): 349–50

Cruz NI, Bayron FE, Suarez AJ (1989) Accelerated healing of full-thickness burns by use of high-voltage pulsed galvanic stimulation in the pig. *Ann Plast Surg* 23(1): 49–55

Cukjati D, Savrin R (2004) Electric current

wound healing. In: Rosch P, Markov M, eds. *Bioelectromagnetic Medicine*. Marcel Dekker, New York: 485–505

Dodgen PW, Johnson BW, Baker LL et al (1987) The effects of electrical stimulation on cutaneous oxygen supply in diabetic older adults. *Phys Ther* 67(5): 793

Feldman D, Andino RV, Jennings JA (2005) Clinical evaluation of an electrical stimulation bandage (Posifect Dressing). Poster presentation at ETRS/EWMA/DFGW Conference, Stuttgart, Germany

Fivenson DP, Faria DT, Nickoloff BJ, Poverini PJ, Kunkel S, Burdick M, Strieter RM (1997) Chemokine and inflammatory cytokine changes during chronic wound healing. *Wound Repair Regen* 5: 310–22

Fukushima K, Densa N, Inui H et al (1953) Studies on galvanotaxis of human neutrophilic leukocytes and methods of its measurement. *Medical Journal of Osaka University* 4: 195–208

Gabbiani G (2003) The myofibroblast in wound healing and fibrocontractive diseases. *J Pathol* 200(4): 500–3

Gardner SE, Frantz RA, Schmidt FL (1999) Effect of electrical stimulation on chronic wound healing: a meta-analysis. *Wound Repair Regeneration* 7(6): 495–503

Goldman R, Pollack S (1996) Electric fields and proliferation in a chronic wound model. *Bioelectromagnetics* 17(6): 450–7

Goldman R, Rosen M, Brewley B, Golden M (2004) Electrotherapy promotes healing and microcirculation of infrapopliteal ischemic wounds: a prospective pilot study. *Adv Skin Wound Care* 17(6): 284–94

Hampton S, King L (2005) Healing an intractable wound using bio-electrical stimulation therapy. *Br J Nurs (Tissue Viabil Suppl)* 14(15): S30–S32

Hansson C, Hoborn J, Moller A, Swanbeck G (1995) The microbial flora in venous leg ulcers without clinical signs of infection. Repeated culture using a validated standardised microbiological technique. *Acta Derm Venereol* 75(1): 24–30

Harding KG, Moore K, Phillips TJ (2005) Wound chronicity and fibroblast senescence; implications for treatment. *International Wound Journal* 2: 336–9

Herrick SE, Sloan P, McGurk M, Freak L, McCollum CN, Ferguson MW (1992) Sequential changes in histologic pattern and extracellular matrix deposition during the healing of chronic venous ulcers. *Am J Pathol*

141(5): 1085–95

Higley HR, Ksander GA, Gerhardt CO, Falanga V (1995) Extravasation of macromolecules and possible trapping of transforming growth factor-beta in venous ulceration. *Br J Dermatol* 132(1): 79–85

Hinman CD, Maibach H (1963) Effect of air exposure and occlusion on experimental human skin wounds. *Nature* 200(4904): 377–8

Houghton PE, Kincaid CB, Lovell M, Campbell KE, Keast DH, Woodbury MG, Harris KA (2003) Effect of electrical stimulation on chronic leg ulcer size and appearance. *Phys Ther* 83(1): 17–28

Illingsworth C, Barker A (1980) Measurement of electrical currents emerging during the regeneration of amputated finger tips in children. *Clin Nays Physiol Meas* 1: 87–9

Jaffe LF, Venable JW Jr (1984) Electric fields and wound healing. *Clin Dermatol* 2(3): 34–44

Kanof NM (1964) Gold leaf in the treatment of cutaneous ulcers. *J Invest Dermatol* 43: 441–2

Kincaid CB, Lavoie KH (1989) Inhibition of bacterial growth in vitro following stimulation with high voltage, monophasic, pulsed current. *Phys Ther* 69(8): 651–5

Kloth LC (1995) Physical modalities in wound management: UVC, therapeutic heating and electrical stimulation. *Ostomy Wound Manage* 41(5): 18–27

Kloth LC (2005) Electrical stimulation for wound healing: a review of evidence from in vitro studies, animal experiments and clinical trials. *International Journal of Lower Extremity Wounds* 4(1): 23–44

Kloth LC, Feedar JA (1988) Acceleration of wound healing with high voltage, monophasic pulsed current. *Phys Ther* 68: 503–8

Kloth LC, McCulloch JM (1996) Promotion of wound healing with electrical stimulation. *Adv Wound Care* 9(5): 42–5

Loots MA, Lamme EN, Zeegelaaar J, Mekkes JR, Bos JD, Middelkoop E (1998) Differences in cellular infiltrate and extracellular matrix of chronic diabetic and venous ulcers versus acute wounds. *J Invest Dermatol* 111(5): 850–7

McGinnis ME, Venable JW Jr (1986) Voltage gradients in newt limb stumps. *Prog Clin Biol Res* 210: 231–8

Markov MS (1995) Electrical current and electro-magnetic field effects on soft tissues: implications for wound healing. *Wounds* 7: 94–110

Mendez MV, Stanley A, Park HY, Shon K, Phillips T, Menzoian JO (1998) Fibroblasts cultured from venous ulcers display cellular characteristics of senescence. *J Vasc Surg* 28(5): 876–83

Moore K (1999) Cell biology of chronic wounds: the role of inflammation. *J Wound Care* 8(7): 345–8

Nishimura KY, Isseroff RR, Nuccitelli R (1996) Human keratinocytes migrate to the negative pole in direct current electric fields comparable to those measured in mammalian wounds. *J Cell Sci* 109(Pt 1): 199–207

Nissen NN, Polverini PJ, Coch AE et al (1998) Vascular endothelial growth factor mediates angiogenic activity during the proliferative phase of wound healing. *Am J Pathology* 152: 1445–52

Orida N, Feldman JD (1982) Directional protrusive pseudopodial activity and motility in macrophages induced by extracellular electric fields. *Cell Motil* 2(3): 243–55

Peters EJ, Armstrong DG, Wunderlich RP, Bosma J, Stacpoole-Shea S, Lavery LA (1998) The benefit of electrical stimulation to enhance perfusion in persons with diabetes mellitus. *J Foot Ankle Surg* 37(5): 396–400

Pol IE, Mastwijk HC, Bartels PV, Smid EJ (2000) Pulsed-electric field treatment enhances the bactericidal action of nisin against *Bacillus cereus*. *Appl Environ Microbiol* 66(1): 428–30

Reger SI, Hyodo A, Negami S, Kambic HE, Sahgal V (1999) Experimental wound healing with electrical stimulation. *Artif Organs* 23(5): 460–2

Rowley BA, McKenna JM, Chase GR, Wolcott LE (1974) The influence of electrical current on an infecting microorganism in wounds. *Ann N Y Acad Sci* 238: 543–51

Schultz GS, Sibbald RG, Falanga V et al (2003) Wound bed preparation: a systematic approach to wound management. *Wound Repair Regen* 11(Suppl 1): S1–S28

Sheridan DM, Isseroff RR, Nuccitelli R (1996) Imposition of a physiologic DC electric field alters the migratory response of human keratinocytes on extracellular matrix molecules. *J Invest Dermatol* 106(4): 642–6

Stiller MJ, Pak GH, Shupack JL, Thaler

S, kenny C, Jondreau L (1992) A portable pulsed electromagnetic field (PEMF) device to enhance healing of recalcitrant venous leg ulcers: a double-blind, placebo-controlled clinical trial. *Br J Dermatol* 127(2): 147–54

Szuminsky NJ, Albers AC, Unger P, Eddy JG (1994) Effect of narrow, pulsed high voltages on bacterial viability. *Physical Therapy* 74(7): 660–7

Taskan I, Ozyazgan I, Tercan M et al (1997) A comparative study of the effect of ultrasound and electrostimulation on wound healing in rats. *Plast Reconstr Surg* 100(4): 966–72

Thawer HA, Houghton PE (2001) Effects of electrical stimulation on the histological properties of wounds in diabetic mice. *Wound Repair Regen* 9(2): 107–15

Venable J, Jr (1989) Integumentary potentials and wound healing. In: Borgans R et al, eds. *Electrical Fields in Vertebrate Repair*. Alan R Liss, New York: 183

Wheeler PC, Wolcott LE, Morris JL (1971) Neural considerations in the healing of ulcerated tissues by clinical electrical therapeutic applications of weak direct current. In: Reynolds DV, Sjoberg AE, eds. *Neuroelectric Research*. Charles C Thomas, Springfield, Illinois: 83

Szuminsky NJ, Albers AC, Unger P, Eddy JG (1994) Effect of narrow, pulsed high voltages on bacterial viability. *Phys Ther* 74(7): 660–7

Winter GD (1962) Formation of the scab and the rate of epithelialisation of superficial wounds in the skin of the young domestic pig. *Nature* 193: 293–4

Wood JM, Evans PE 3rd, Schallreutter KU et al (1993) A multicenter study on the use of pulsed low-intensity direct current for healing chronic stage II and stage III decubitus ulcers. *Arch Dermatol* 129(8): 999–1009

van Rijswijk L (2006) Ingredient-based wound dressing classification: a paradigm that is passé and in need of replacement. *J Wound Care* 15(1): 11–14

Zhao M, Dick A, Forrester JV, McCaig CD (1999) Electric field-directed cell motility involves up-regulated expression and asymmetric redistribution of the epidermal growth factor receptors and is enhanced by fibronectin and laminin. *Mol Biol Cell* 10(4): 1259–76

Zhao M, Bai H, Wang E, Forrester JV, McCaig CD (2004) Electrical stimulation directly induces pre-angiogenic responses in vascular endothelial cells by signaling through VEGF receptors. *J Cell Sci* 117(Pt 3): 397–405